

Clinical & Refractive Optometry is pleased to present this continuing education (CE) article by Dr. Ron Melton and Dr. Randall Thomas entitled **Vernal Keratoconjunctivitis**. In order to obtain a 1-hour Council of Optometric Practitioner Education (COPE) approved CE credit, please refer to page 52 for complete instructions.

Vernal Keratoconjunctivitis

Ron Melton, OD; Randall Thomas, OD

SUBJECTIVE

An 8-year-old black boy was brought to the office by his parents with a chief complaint of severe itching for several days. Pharmacist-recommended over-the-counter (OTC) allergy drops have been of little help. He had a similar episode of itching last spring as well; otherwise he was healthy.

OBJECTIVE

- Visual acuity was 6/6 (20/20) OU
- There was minimal injection in primary gaze
- Down gaze revealed marked injection at the superior limbus in both eyes (Fig. 1)
- There was peripheral corneal edema superiorly
- Fluorescein staining revealed corneolimbal microcystic edema as well as some conjunctival epithelial staining (Fig. 2)
- Lid eversion was normal
- There was some mucus excess

ASSESSMENT

- Classic limbal vernal conjunctivitis

PLAN

- Prescribed prednisolone sodium phosphate 1% (Inflamase Forte) q.h. for two days, then q.2h., for two more days
- Return for follow-up in four days

R. Melton, R. Thomas — Adjunct faculty members at the Pennsylvania, Pacific University and SUNY Colleges of Optometry; Consultants to the American Optometric Association and Fellows of the American Academy of Optometry; both are in clinical practice in North Carolina. Recipients of the Glaucoma Educators of the Year Award presented by the American Academy of Optometry.

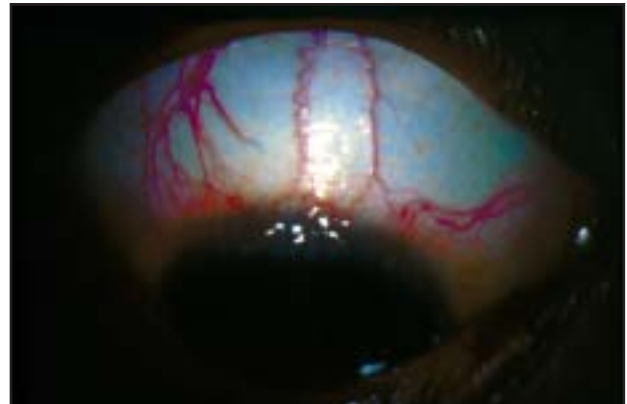

Fig. 1 Note the edematous corneolimbal tissues and the paralimbal injection pattern.

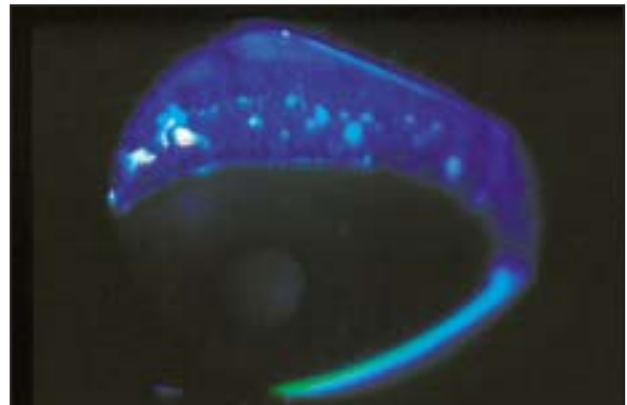


Fig. 2 There is so much inflammation that punctate staining of the edematous conjunctival epithelium is present.

First Follow-Up Visit (Four Days Later)

- Patient was asymptomatic
- All tissues were clinically renormalized (Figs. 3, 4)
- There was excellent (typical) response to steroid pulse dose suppression of vernal disease
- Continue prednisolone sodium phosphate 1% q.i.d. for four days, then b.i.d. for four days
- Start mast cell stabilizer [pemirolast potassium 0.1% (Alamast)] q.i.d. to alternate concurrently with prednisolone sodium phosphate 1%

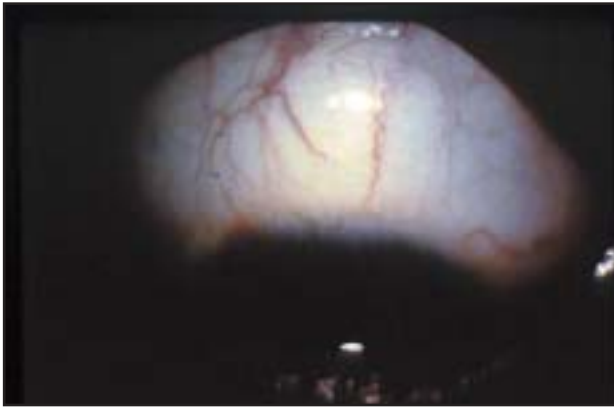


Fig. 3 Following frequent use of prednisolone sodium phosphate 1% for four days, the previously inflamed tissues are renormalized.

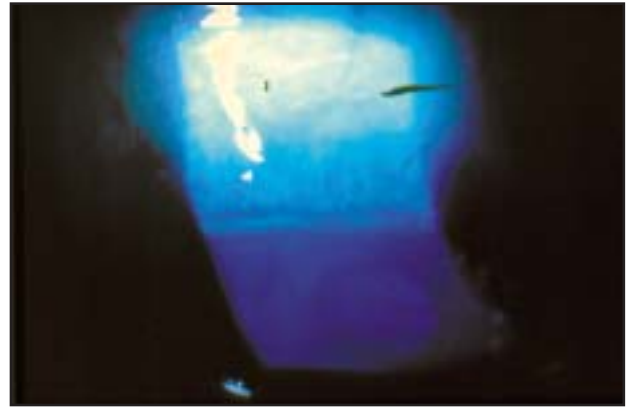


Fig. 4 Note the disappearance of the active fluorescein staining pattern after a few days of steroid therapy.

After Eight Days

- After eight days, the steroid therapy will be completed and good mast cell stabilization should have occurred which should keep the patient asymptomatic for the duration of his vernal “at risk” period. The mast cell stabilizer is continued q.i.d. for one month and b.i.d. for another month
- He is to return in two months for follow-up and a baseline comprehensive eye examination
- His parents were thoroughly educated as to the chronic recurrent nature of vernal disease and advised to bring him in immediately if he has a symptomatic flare-up

Comments: This patient is a classic case of limbal vernal conjunctivitis. These patients may be plagued with numerous flare-ups during their childhood years. Cold compresses and oral antihistamines may occasionally be helpful. The key is to rapidly suppress the acute condition with the aggressive use of potent steroids. As soon as control is achieved, begin a rapid taper while blending in a mast-cell stabilizer. These much safer agents are very useful for chronic maintenance without the potential for side effects that steroids carry. The tarsal form of vernal conjunctivitis is extremely rare.

GENERAL OBSERVATIONS

- This condition is an expression of severe allergic disease, therefore seasonal in incidence
- It is seen mostly in males, ages 6 to 16
- While it is usually bilateral, asymmetry is common
- Symptoms include: itch, blepharospasm, photophobia, and a ropy/mucoid discharge
- Two forms exist: tarsal conjunctival disease and limbal disease

- Tarsal form can cause a pseudo-ptosis, and lid eversion shows advanced giant papillary conjunctivitis (GPC)-like papillary hypertrophy covering most of the superior tarsal conjunctiva
- Limbal form (seen mostly in black, male children) shows a limbal and paralimbal conjunctival vascular injection pattern with Trantas’ dots (these are most common at the superior corneolimbus). The edematous limbal and paralimbal tissues have a mild, milky-white gelatinous appearance. Trantas’ dots are aggregates of eosinophils and degenerated epitheloid cells
- Treatment must be tailored to individual cases. Pulse dosing with 1% prednisolone, 1% rimexolone, or 0.5% loteprednol is the cornerstone of medical management. However, once control is gained, and the tapering process begins, adding a mast cell membrane stabilizing agent (pemirolast potassium 0.1%) can be helpful in maintaining symptomatic control. This adjunctive therapy nicely bridges the gap between acute flare-ups, and helps minimize the use of corticosteroids in this chronic, recurrent disease
- This disorder tends to self-limit after two to eight years

Disclaimer: Not every detail of every case is discussed, rather the key clinical findings are described. For example, if nothing is said about the corneal status, you should assume that the cornea is normal, etc. When vision is recorded, it should be assumed to be best corrected or pinholed. Regarding therapy, we show how we treated the particular case. Given that medicine is an art, as well as a science, therapy will — and often does — vary with each unique patient presentation depending on severity, known drug allergies, prior treatment, response to therapy, etc.



INSTRUCTIONS FOR CE CREDITS

In order to obtain a 1-hour COPE-approved CE credit, please follow these steps:

- Fill in the identification section and answer the 10 multiple choice questions in this CE credit application form
- Prepare a cheque for \$25.00 made out to Medicconcept
- Mail your completed CE credit application form and cheque to the Journal at: *Clinical & Refractive Optometry*, 3333 Cote Vertu Blvd., Suite 300, St. Laurent, Quebec H4R 2N1

Your answers will be sent for marking to the School of Optometry, University of Montreal, Quebec. If you score 70% or more, a COPE-approved CE Credit Certificate will be issued by the University of Montreal and *Clinical & Refractive Optometry* for your records and display in your office.

IDENTIFICATION

Name: First _____ Last _____

Address: _____
Number Street Suite

_____ City Province Postal Code

Office Phone: () _____ Fax: () _____ e-mail: _____

Registration Number: _____

QUESTIONNAIRE

Contact Blepharodermatitis

Ron Melton, OD; Randall Thomas, OD

1. The patient presented with a recent history of:
 - dry eye
 - corneal edema
 - itching and redness of the eye
 - an allergic ocular reaction to a known allergen
2. Which one of the following is **TRUE**?
 - The patient reported significant improvement following the use of Benadryl
 - The patient had not tried Benadryl
 - The patient reported only little relief with Benadryl
 - The patient was overusing Benadryl
3. Which of the following is **TRUE**?
 - The patient had significant dryness to the affected skin tissues
 - The patient had mild dryness to the affected skin tissues
 - There was no conjunctiva involvement
 - There was no cornea involvement
4. Which of the following is **TRUE**?
 - The lower lid is particularly predisposed to manifesting blepharodermatitis
 - The upper eyelid is particularly predisposed to manifesting blepharodermatitis
 - Both the upper and lower eyelids are predisposed to manifesting blepharodermatitis
 - Neither the lower nor the upper eyelid is predisposed to manifesting blepharodermatitis

5. Which one of the following is **FALSE**?
 - Rubbing the eyelid can not cause a reactive, inflammatory blepharodermatitis
 - Rubbing the eyelids is part of the patient's subjective reporting
 - Prescribed medication can diminish the symptoms
 - The etiology of the condition was not yet determined

6. Which one of the following statements is **TRUE**?
 - The plan is to prescribe fluoromethalone
 - The plan is to increase the fluoromethalone at bedtime
 - The plan calls for the use of cool compresses during the day
 - All of the above

7. Which one of the following statements is **TRUE**?
 - The erythema resolved completely in four days
 - Cool compresses were not suggested by the practitioner
 - The erythema did not clear up for two weeks following the patient's first visit
 - The plan did not call for a determination of the etiology of the condition

8. Which one of the following statements is **FALSE**?
 - Therapy consisted of applying a steroidal ophthalmic ointment
 - Fluoromethalone ointment is not used for contact blepharodermatitis
 - Sodium sulfacetamide/steroid combination is an alternative to fluoromethalone
 - In combination sodium sulfacetamide/steroid therapy, the sulfacetamide performs no therapeutic role for the underlying inflammation

9. Which of the following statements is **TRUE**?
 - Prednisolone cream is not indicated for contact blepharodermatitis
 - Sodium sulfacetamide plays a role in therapy
 - Hot compresses bring relief and resolution of the inflammation
 - Triamcinolone cream 0.1% is the drug-of-choice in most inflammatory/allergic eyelid disorders

10. Which one of the following statements is **FALSE**?
 - Triamcinolone cream is a very expensive alternative to FML ointment
 - Continuous weeping or drainage of ocular fluids can cause maceration of the ocular skin tissues
 - If contact blephardomeratitis persists, allergy testing is indicated
 - Corticosteroids are the mainstay of treating the acute presentation of inflammatory dermatitis